e-planet **16** (1): 79-84 (June 2018)

Prevailing human - hyena conflict in Agra district, Uttar Pradesh, India and conservation strategies

S. ILAYARAJA [1], A. SHA. ARUN[2*] AND M.V. BAIJU RAJ [3]

[1]Deputy Director, Veterinary Services, [2]Director, Research and Veterinary Operations, [3]Director, Conservation Project, Wildlife SOS, India.

**arun@wildlifesos.org*

Date of receipt: 20.11.2017 Date of acceptance: 08.06.2018

ABSTRACT

The striped hyena (*Hyaena hyaena*) is a species of the smallest of the true hyenas listed by the IUCN as near-threatened. Wildlife SOS (a non-profitable Non Governmental Organisation) with assistance from Forest department has been dedicated to work on rescue and rehabilitation of these animals as a part of conflict mitigation and concentrating to create awareness by conducting various wildlife awareness education programs in schools and villages. The human wildlife conflict involving elephants, tigers and leopards are well documented, but that of hyena is not much explored. The striped hyena (*Hyaena hyaena* L. 1758) is a near threatened large carnivore. However, it possesses a wider distribution range than other hyena spp., the available information about its status and ecology is very limited. This study recorded six such cases encountered during 2015 to 2017. In total, seven animals were rescued and four hyenas (2M: 2F) were released after treatment, two females were dead due to massive injury and one female hyena is still under care as it became blind. The study revealed that conflict increases in winter season and females are more victimized than males.

Key words: Anthropogenic pressure, human-wildlife conflict, striped hyena, wildlife rescue

INTRODUCTION

Over the years, increased anthropogenic pressure coupled with the expansion of agriculture lead to the depletion of the territory and prey base of wildlife species residing in these environments (Mills and Hofer, 1998; Alam et al., 2015). As a result, animals such as hyenas are forced to venture into human settlements in search of food and water for survival. Most often they prey on domestic animals and livestock. Wildlife is accountable for the loss of 3% of livestock per year (Jackson and Nowell, 1996). A number of different wild animals are involved in such conflicts, but, it is aggravated when large carnivores are involved (Dickman, 2008). Man wildlife conflict primarily involves inter specific competition for resources which automatically jeopardizes the lives of the local people and leads to economic losses as well (Sillero-Zubiri and Laurenson, 2001). These conflicts mainly occur at the forest edges and in those areas where the predators have easy access to the livestock without getting noticed (Woodroffe and Ginsberg, 1998). Occurrence of conflicts has increased in recent decades. Anthropogenic activities have escalated in almost every eco-zone owing to gradual elevation in need for daily subsistence (Vitousek et al., 1997). In fact, it is this unrestricted desire for space and subsistence that have initiated fragmentation of forests and habitats and augmented conflicts over available resources even at the national level (Laurance and Bierregaard, 1997; Mishra, 1997).

Carnivores mostly attack livestock that are grazed in forest lands and in human settlements which also poses a risk to human lives. The damage inflicted on humans or on their livelihood often infuriates the herd owners who resort to measures to avenge the loss (Conforti and de Azevedo, 2003).

The striped hyena (*Hyaena hyaena* L. 1758) is a near threatened large carnivore with a wider distribution range than other hyena species. Hyaenidae family consists of four species around the globe such as striped hyena, spotted hyena, brown hyena, and Aardwolf (Mills and Hofer, 1998). They are mostly a scavenger by habit (Prater 1971). Some hyena species are considered as proficient hunters. They seek their food by scent (Prater 1971, Kruuk 1976). These carnivores are playing an important role in maintaining forest and grassland ecosystem (Millls and Hofer, 1998; Abi-said and Abi-said, 2007). Of the four extant hyena species, only the striped hyena is found in India. The striped hyena is categorized as Near Threatened by the IUCN (Arumugam et al. 2008) and placed in schedule-III.

The total Indian population estimate is around 1000 to 3000 individuals representing around 18-20 per cent of the total world population (Mills and Hofer, 1998). The populations are generally declining throughout their geographical range due to persecution, poisoning and hunting for meat or medicinal purpose, besides depletion of prey populations and wildlife diseases (Singh et al., 2010; Akay et al., 2011; Jnawali et al., 2011; Dejene et al., 2016). Other ecological factors such as scarcity of food and shelter may also be contributing to the decline, including diminishing food stocks and competition with other carnivores over shelter (Alam, 2011, Akay et al., 2011, Khorozyan et al., 2011). Assessment of the status and distribution of animals to monitor population trends in case of rare or endangered species is a key ecological parameter for understanding ecology and conservation status of a species (Williams et al., 2002).

Keeping view of this, conflict between human and the hyena was studied in and around Agra district of Uttar Pradesh, India to support the conservation strategies and record the fact involved in human-hyena conflict.

MATERIALS AND METHODS

The study was conducted in Agra district of Uttar Pradesh at the Wildlife SOS managed rescue centre, where the rescue calls were received from the local forest department or villagers. Six rescue calls were received during the study years (2015 to 2017). The Wildlife SOS rapid response team responded and rescued the animals from a brutal fate due to the rash and violent action of the frightened and angry villagers, the details are as here under.

Case I

A female hyena was rescued on 15 December 2015 from Naroli village (27°27'24.59"N 77°39'58.39"E) in a comatose condition with swollen face, wounds on the body and protrusion of the left eyeball (Fig. 1). The detail radiographic examination revealed a fractured zygomatic bone on the left side.

Fig. 1. Hyena recovered after treatment, but lost vision in right eye

Case II

A female hyena was rescued from a village Kaveesha, Sarvathpur (N 27° 09.19' E 078° 08.837') on 22 March 2016 with a swollen face and multiple

injuries all over the body (Fig. 2). The radiographic examination did not reveal any major injuries to the bones except soft tissue swelling.

Fig. 2. Hyena recovered from multiple injuries and released

Case III

A female hyena was rescued from a mud cave near an agricultural field from village Nagalakeso, Daukethana on 05 April 2016 (Fig. 3). The angry mob was started destroying the cave with JCB to kill the hyena. After huge difficulty, the hyena was safely rescued without any injury. One Nilgai carcass was also recovered from the mud cave. The animal's abdomen was bulged and mild enlargement in nipples also noticed. Initially, pregnancy was suspected. Later, the detail radigraphic examination revealed that there were partially digested feed material in the stomach and no evidence of pregnancy thereof. Since there was no pyometra, it can be taken as pseudo pregnancy.

Fig. 3. Healthy non pregnant hyena released after confirmed with radiographic examination

Case IV

An adult female hyena was rescued in a recumbent condition with facial swelling from Nagla Parasukh, Etamadpur Range, Agra on 25 February 2017 (Fig. 4). The animal was dragging its body as it was unable to stand and walk. The detailed radiographic examination revealed a severe fracture, in dorsal lumbar spine and also in the proximal end of femur bone. There were lacerated injuries also on the body.

Fig. 4. Hyena rescued with paralysis due to multiple fractures

Case V

One female hyena was rescued from Jainpura village, Fatehpursikari (N 27° 06.926' E 077° 40.492') on 05 February 2017 (Fig. 5). The animal was badly chased by the villagers including stone pelting. The animal fell into the drainage channel, which was marshy with dirty stagnated water. The animal was rescued with the help of nets and dog catcher without any chemical immobilization. The examination revealed that the animal was unable to bear weight on its hind limbs and bleeding from the inguinal region. The detail radiographic examination revealed a fracture at the right hip joint and rupture of the rectum leading to escape of faecal matters. Ultrasound examination revealed that the urinary bladder was abnormally distended.

Fig. 5. Hyena rescued with massive hip joint fracture receiving treatment

Case VI

Two adult male hyenas were rescued from a 15 feet dry well from Pinahat (26° 53' 11.91" N 78° 22' 22.37" E) on 01 November 2017 (Fig. 6). Fortunately, there was no fracture except minor injuries. The animals were highly stressed, dehydrated and hungry as well. So after rescue, they were put in a separate covered cage, fed with water mixed with ORS and kept under observation. Anti-inflammatory pills administered orally by hiding it in the meat pieces, then released successfully (Fig. 6).

Fig. 6. Two male hyena rescued from the well and released.

RESULTS AND DISCUSSION

The treatments to the injured animals and further steps taken were described in the following:

Case I

The left eye ball was protruded excessively with hemorrhage. Surgical correction was tried, but it was unsuccessful and had to be extirpated (Venugopalan, 2002). The animal was kept in RT (the small enclosure to restrict movement) as it could have hampered the healing of the wound. Subsequent treatment was given to stabilize the condition. The animal recovered well from all injuries except the vision of the right eye. The brutal head injury might have led to damage of the optic nerve which could have resulted in permanent blindness of the right eye, which made the animal unfit for releasing back in the wild (Fig. 1)

Case II

The animal released back into the wild after it was recovered (Fig. 2).

Case III

The animal was kept under observation and released back into the wild (Fig. 3)

Case IV

Subsequent treatment was given, but animal succumbed to injuries the animal had sustained (Fig. 4).

Case V

The urinary catheter was fixed to empty the bladder; blood mixed urine was coming out. Necessary critical care was given, but the animal succumbed to injuries. Postmortem examination revealed a ruptured peritoneal cavity filled with blood and feces (Fig. 5).

Case VI

After observation period of two days, the animals were recovered from stress and were fit for release. We suspected both the males were fighting over territory and accidentally fell in the open well at night. Stone pelting by the villagers started by next morning onwards. So the decision was made to release the animals in two separate locations in order to avoid further infighting as they happen to be solitary animals.

Out of seven animals rescued, two (females) passed away, one female kept in our custody as

the animal became blind and rest (2 males and 2 females) were released into suitable habitats. This was the clear evidence of high intensity conflict between human and hyena. Winter season had more cases. Female hyenas were more involved in conflicts than the males (Fig. 7).

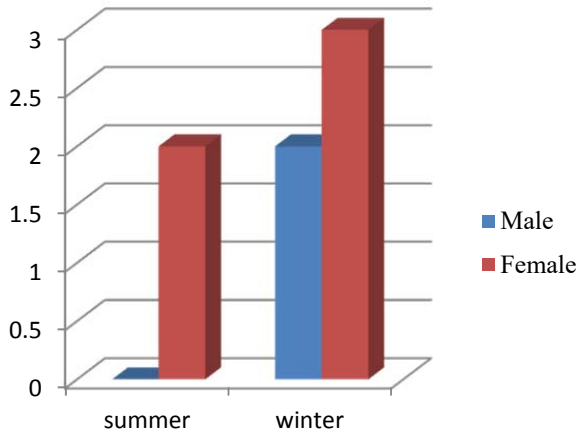

Male & Female rescued season wise

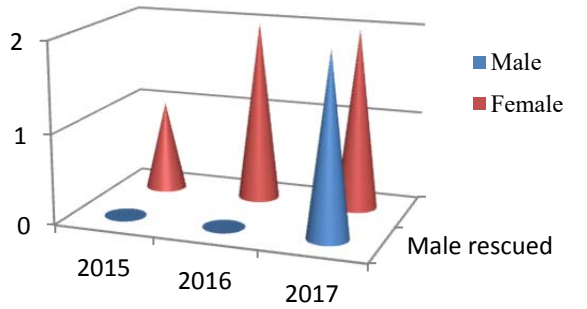

Male & Female rescued year wise

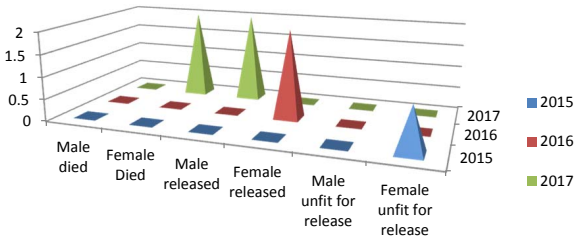

Year wise detail of Male& Female mortality, release and Unfit for release

Fig. 7. Detail summary of hyena rescued, released and mortality

Thus, keeping in view the importance of the issue, there is an imminent need to educate the public to increase tolerance towards wild animals in an attempt to mitigate human-wildlife conflicts. The factors such as the nocturnal habit of hyena, solitary behavior and occurrence in low densities are further increasing the complication towards the assessment of current status and population trends of the striped hyena. The questionnaire surveys, extrapolation, Lincoln index, identification of individuals and tracks, signs and vocalizations (Mills, 1998) and capture-recapture method using photo camera trap (Karanth, 1995) may be used for striped hyena.

CONFLICT MITIGATION STRATEGIES

The human-hyena conflict can be reduced by developing certain precautionary measures to minimize the risk, such as effective nocturnal livestock management and herding during daytime. The strategies that could be implemented in an attempt to lower livestock loss may include enhanced guarding and construction of predator-proof pens. Encouragement of the better breeds of guard dogs could greatly reduce depredation or avoid predator form the livestock. The livestock insurance scheme should be introduced in this area to compensate the poor villagers.

Further studies need to be initiated to assess the current status and population trends of striped hyena in India to develop an effective conservation modality for this species.

REFERENCES

Abi-Said, M.R and Abi-Said, M.D. 2007. Distribution of the striped hyena (*Hyaena hyaena syriaca* Matitus,1882) (Carnivora: Hyaenidae) in urban and rural areas of Lebanon. *Zool. Middle East.* **42**(1): 3-14

Akay, A.E., Inac, S. and Yildrim I.C. 2011. Monitoring the distribution of striped hyenas (*Hyaena hyaena* L) in the Eastern Mediterranean Region of Turkey (Hatay) by using GIS and remote sensing technologies. *Environ. Monit. Assess.* **181**:445-455

Alam, M.S. 2011: Status ecology and conservation of striped hyena (*Hyaena hyaena* L) in Gir National Park and Sanctuary, Gujarat, India.