



# Molecular detection of *Theileria* spp. in apparently healthy cervids of Nandankanan Zoological Park, Odisha

S.K. SAHU<sup>1</sup>, S.R. HOTA<sup>2</sup>, B.K. BEHERA<sup>2</sup>, M. DASH<sup>2</sup> AND N. SAHOO<sup>1\*</sup>

<sup>1</sup>Nandankanan Zoological Park, Forest and Environment Department, Government of Odisha, India

<sup>2</sup>Centre for Wildlife Health, College of Veterinary Science and Animal Husbandry, Odisha University of Agriculture and Technology, Bhubaneswar-751003, Odisha, India

\*niranjanasahoo@hotmail.com

Date of receipt: 10.09.2019

Date of acceptance: 17.12.2019

## ABSTRACT

*Theileria* spp., predominantly a tick-borne haemoprotozoan parasites of cattle, do infect wild animals especially in endemic areas. Identification of infectious agents provides valuable information on epidemiology. Molecular study was conducted in two species of wild cervids, i.e., brow-antlered deer and sambar deer of Nandankanan Zoological Park (NZP), Bhubaneswar, Odisha to assess the occurrence of blood pathogen. Following DNA extraction from the whole blood samples, the product was subjected to PCR with 989/990 primers specific for *Theileria* genus where a product size of 1098bp upon gel electrophoresis were recorded in positive cases. Out of 9 brow-antlered deer and 12 sambar deer samples processed, 8 samples (4 from each species) showed presence of *Theileria* spp. indicating a prevalence rate of 38 per cent. The study uncovered the carrier stage of *Theileria* spp. among wild cervidae population in NZP and thereby laid down stepping stone towards control measures.

**Key words:** Carrier stage, Nandankanan Zoological Park, PCR, theileriosis, wild cervid

## INTRODUCTION

The genus *Theileria*, comprising of obligate intracellular haemoprotozoan parasites, have the ability to infect both domestic as well as wild ruminant throughout the world (Garcia-Sanmartin et al., 2007). Apart from its economic effect on domestic bovines in the form of low productivity or mortality, this tick-borne disease has also been reported to infect wild ruminants like white-tail deer (Schaeffler, 1961), elk (Chae et al., 1998), sika-deer (Inokuma et al., 2004), mule deer (Kjemtrup et al., 2000), fallow deer (Galuppi et al., 2010) and water deer (Han et al., 2009). Some species of the genus *Theileria* such as *T. annulata* and *T. parva* are highly pathogenic and cause significant mortality among susceptible animals (Tait and Hall, 1990; Gitau et al., 1999). However, other *Theileria* spp. like those

of *T. orientalis/buffeli* group are considered to be benign or less pathogenic probably because of a long evolutionary relationship between the parasite and the host (Zanet et al., 2014). Nevertheless, clinical disease may occur in stressful situations related to translocation, concurrent diseases or malnutrition (Kocan and Kocan, 1991; Hofle et al., 2004; Sawczuk et al., 2008).

*Theileria* spp. are cosmopolitan parasites (Chae et al., 1999) that have been detected in wild ruminants in many countries including Japan (Ikawa et al., 2011), South Korea (Han et al., 2009), Brazil (Silveira et al., 2013), the United States (Garner et al., 2012), Italy (Galuppi et al., 2010), Austria (Fuehrer et al., 2013) and Spain (Garcia-Sanmartin et al., 2007). Though India has long been established as a victim of bovine theileriosis,

reports of theileriosis among wild animals are scant. Literature search on the incidence of theileriosis among domesticated bovines in India over the last four decades has revealed the existence of theileriosis in clinical as well as carrier stages (Anonymous, 2015; Kakati et al., 2015). The occult infection may remain as a potential source of infection for other susceptible hosts. But there is lack of information on prevalence of such infection among wild animals in India that is essentially required to chalk out effective location specific control programme.

Keeping the above facts in forefront, the present study was conducted to unveil status of *Theileria* spp. infection, if any, by blood smear examination and polymerase chain reaction (PCR) in two different species of wild cervids viz. brow-antlered deer (*Rucervus eldii*) and sambar deer (*Rusa unicolor*) maintained separately under captivity in Nandankanan Zoological Park (NZP), Bhubaneswar, Odisha, one of the largest zoos of India.

## MATERIALS AND METHODS

Odisha is privileged to own NZP, one of the premier zoological parks across India, which is geographically located between 20° 23' 08" to 20° 24' 10" N latitude and 85° 48' 09" to 85° 48' 13" E longitude. Of huge repertoire, wild ruminants constitute a major chunk. The state experiences moderately hot and very humid climate favouring rapid multiplication of vectors and propagation of vector-borne diseases of which theileriosis is one with economic repercussions (Ogre, 1999). Five species of theileria (*T. annulata*, *T. parva*, *T. taurotragi*, *T. velifera* and members of *T. sergentii/orientalis/buffeli* group) have been found to infect animals throughout the world. The state of Odisha has also witnessed reports of theileriosis among domesticated bovines in its coastal districts. But the report of this disease among wild animals of Odisha is silent. Therefore, the need to unveil the picture of theileriosis in the wild mammals is of paramount importance.

During the process of therapeutic management, there was a need of collecting whole blood samples

from two different species of wild *Cervidae* i.e., Brow-antlered deer and Sambar deer for hemato-biochemical analysis. Such blood samples were screened for presence of *Theileria* spp. using conventional blood smear examination and PCR.

Approximately one millilitre of blood sample was collected properly from jugular vein of nine Brow-antlered deer and 12 Sambar deer each belonging to both sexes in EDTA coated vacutainers, during restraint for therapeutic management and surgical interventions. Such samples were brought to the Centre for Wildlife Health, OUAT for laboratory investigation.

### Microscopic examination (ME)

Thin blood smears prepared from whole blood samples were fixed with methanol for 5 minutes and subjected to staining with 10% Giemsa's solution for 40 minutes. Blood smears were carefully examined for presence of *Theileria* spp. parasites under the oil immersion lens (100 X magnifications).

### Molecular diagnosis through PCR

Genomic DNA was extracted from each blood sample using commercially available DNA mini kit (QIAGEN, GERMANY). According to the manufacturer's instructions, 200 µl of whole blood was used for each sample. The integrity of extracted DNA was checked by agarose gel electrophoresis. Purified DNA was used as template for the PCR. In PCR, 989/990 set of primers were used specific for *Theileria* genus (Table 1). PCR was performed in a final reaction volume of 25 µl reaction mixtures containing 2 µl DNA sample (using 30 ng µl<sup>-1</sup> template in case of DNA reference samples), 50 mM KCl, 10 mM Tris-HCl (pH 8.3), 1.5 mM MgCl<sub>2</sub>, 200 µM of dNTP mix, 20 pmol of each primer, 0.5U Taq polymerase enzyme and sterile distilled water up to 25 µl. The reaction mixture was placed on a heating block of a Proflex PCR system (Thermofischer scientific). After a denaturation step of 5 min at 94°C, each of 30 cycle consisted of 1 min at 94°C, 1 min at 55°C, 1 min at 72°C followed by 10 min at 72°C. Positive control and negative control were run along with

the test samples. The amplification products were subjected to electrophoresis on 1.5 per cent agarose gel with ladder and the amplified products were

visualized using Gel Documentation system. A product size of 1098 bp by primers 989/990 were considered positive for *Theileria* genus

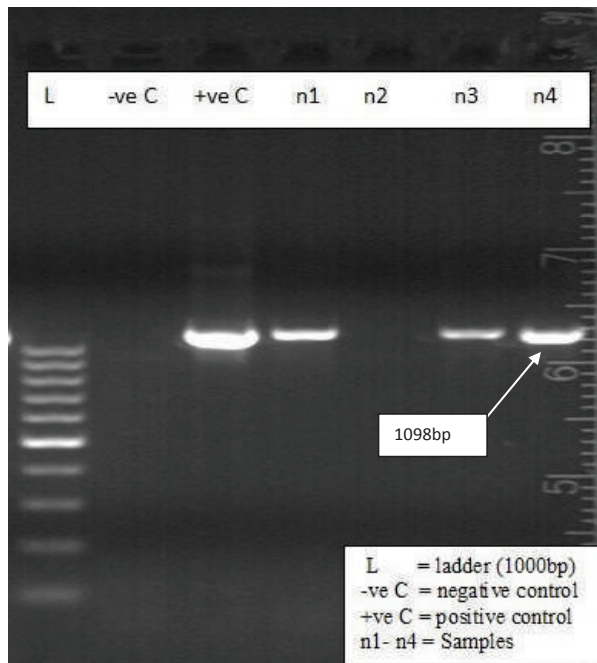
**Table 1.** Primer set used for PCR to detect *Theileria* spp.

Oligo name	Sequence (5'----> 3')	Product size	Target genome
989	GTAACCTTTAAAAACGT	1098 bp	<i>Theileria</i> genus specific
990	GTTACGAACATGGGTTT		

Source: Vet. World, Prevalence of theileriosis in cross-bred cattle authored by Kohli et al. (2014)

## RESULTS AND DISCUSSION

On microscopic examination, all 21 blood smears examined were found negative for the presence of both the stages of *Theileria* parasite i.e., piroplasm and/or schizonts under 100X resolution by oil immersion. However, molecular detection through PCR revealed a more elaborate picture where 8 (38 %) cases found positive for *Theileria* spp. (Fig. 1). Out of these, 4 positive samples belonged to Brow-antlered deer and the rest four were from Sambar deer.



**Fig. 1.** Gel image showing positive amplification of *Theileria* spp. in wild cervids (Brow-antlered deer and Sambar deer) and amplicon size in base pairs.

*Theileria* sp. is an obligatory intracellular parasite that exhibit indirect lifecycles. *Ixodid* spp. (hard ticks) belonging to the genus *Rhipicephalus*, *Hyalomma*, *Haemaphysalis* and *Amblyomma* have been reported to be the vectors for different species of *Theileria* parasites across the globe. *Theileria* sporozoites are transmitted to susceptible animals in the saliva of the feeding tick. In cattle the disease is characterized clinically by pyrexia, inappetance, swollen peripheral lymph nodes, anaemia and icterus. Other clinical signs include lacrimation, corneal opacity, nasal discharge, terminal dyspnoea and diarrhoea. In wild animals, though carrier stages are seen in a number of bovids and cervids, clinical infection has been reported in a gaur calf (*Bos gaurus*) in India with clinical signs of opacity of both eyes, reduced appetite, clay coloured stool loose in consistency, champing of jaws and pyrexia. Outside India, clinical infections have been documented in Sika deer in China with symptoms of pale mucous membrane, weight loss and swollen prescapular lymph nodes (Liu et al., 2016). Fatal infections have also been recorded in African antelopes where clinical signs observed were depression, drooping of the ears, prolonged intermittent recumbency, anorexia, and lagging behind the herd. On inspection after immobilization, the animals were found to be anemic, icteric, and pyrexia, with generalized lymph node enlargement and prolonged bleeding times. Nijhof et al. (2005) recorded icterus and widespread petechiae (especially in the renal cortex), splenomegaly, red pulp hyperplasia, pulmonary edema, and a generalized lymphoid hyperplasia in antelopes during postmortem examination. Punched ulcers in the abomasums, a characteristic pathognomonic lesion in cattle, was not noticed.

Though the conventional Giemsa stained thin blood smear examination continues to be the gold standard method for identification of intra-erythrocytic piroplasm and schizont stage of *Theileria* spp., this method is rarely successful in case of carrier animals (Durrani and Kamal, 2008). Such statement substantiates the findings in the present study where none of the thin blood smears were positive for *Theileria* parasites under microscopy. Moreover, by microscopic examination, it is generally not possible to discriminate different species of *Theileria* spp. that may occur as single or mixed with other species simultaneously within the same host (Parthiban et al., 2010). The serological tests like IFA and ELISA are also not suitable due to cross reactivity with other *Theileria* spp. (Anonymous, 2014) and inability to distinguish between active carriers and animals with antibodies due to prior infections (Dolan, 1986).

In the present investigation, PCR could identify *Theileria* spp. in 38 % (8/21) of the apparently healthy wild cervids of NZP that established the carrier status of this parasite. To the best of our knowledge, this study is probably the first of its kind to report *Theileria* infection in cervids in India. Appearance of carrier animals is a cause of concern as it poses as a risk and focus of infection to other susceptible healthy animals in the zoo viz., Four horned antelopes, Blackbuck, Mouse deer, Swamp deer, Barking deer, Hog deer, Sambar deer, Spotted deer, Brow-antlered deer and Nilgai. In addition to that, there is a herbivore safari in the park that inhabits four of these species that are Barking deer, Spotted deer, Sambar deer and Four horned antelopes which creates a greater risk of transmission of this parasite among the wild herbivores.

Carrier animals are usually the chronic form of piroplasms (Kohli et al., 2014). It could be inferred that the carrier animals along with the tick feeding on them may act as the source of infection for the healthy population. They usually remain undetected by conventional microscopic and serological methods due to low level of infection (Roy et al., 2000). To overcome these constraints,

PCR was preferred for its high sensitivity and the ability to amplify even a minute concentration of parasitic DNA in the blood enabling the detection of carrier animals especially in endemic conditions (Mans et al., 2015).

Livestock could also be a possible source of this parasite to wildlife population in the buffer areas (Daniels, 2007). It is a fact that some species of *Theileria* have also been found capable of being mechanically transmitted to healthy cattle by minute volumes of blood through intravenous inoculation by hypodermic needle as well as through biting arthropods (Hammer et al., 2016) which further escalates the risk factor associated with the carriers of this disease. An inverse relationship exists between age and resistance to infection, where fawns gradually acquire immunity without showing clinical symptoms, and immunity is maintained by repeated challenges with the parasites. Consequently, a persistent parasite reservoir is established in the wild ruminants (Garcia-Sanmartin et al., 2007). It has already been established that stressors like high parasitemia, poor nutrition, high population density, harsh weather conditions, or handling (e.g. translocation) can lead to symptomatic piroplasmosis which is a cause of severe disease and death among wild animals (Hofle et al., 2004).

Buparvaquone with/without oxytetracycline is considered effective against theileriosis. However, treatment with these agents does not completely eradicate theileria infections, rather leads to the development of carrier state in that hosts. Reliable live vaccines of known efficacy are available only against species *T. annulata*. But its use in carrier animals is still under scrutiny.

More sustainable and reliable methods for the control of theileriosis include deployment of a combination of strategic tick control and specific attention towards tick or parasite screening in imported animals (Radostitis et al., 2009). Hence, findings of the study will stimulate implementation of preventive practices in the Nandankanan Zoological Park to restrict hemoparasite transmission.

## CONCLUSION

Present study indicated asymptomatic carrier state of *Theileria* spp. in wild cervids i.e., like brown-antlered deer and Sambar deer in Nandankanan Zoological Park, Odisha. Though conventional blood smear examination could not detect presence of piroplasm/schizont in blood smear, PCR could detect *Theileria* spp. in 38 % (8/21) of the apparently healthy wild cervids.

## ACKNOWLEDGEMENT

Authors express their deep sense of thanks and gratitude to the Director, Nandankanan Zoological Park, Forest and Environment Deptt., Govt. of Odisha and Dean, College of Veterinary Science and Animal Husbandry, OUAT, Bhubaneswar-751003, Odisha for their kind support to undertake the study.

## REFERENCES

- Anonymous. 2015. NDDDB - Animal Health Updates, *Quarterly Newsletter* 3(4).
- Anonymous. 2014. *Office International Epizootics (OIE) Terrestrial Manual*. Chapter 2.4.16.
- Chae, J.S., Lee, J., Kwon, O., Holman, P.J., Waghela, S.D. and Wagner, G.G. 1998. Nucleotide sequence heterogeneity in the small subunit ribosomal RNA gene variable (V4) region among and within geographic isolates of *Theileria* from cattle, elk and white-tailed deer. *Vet. Parasitol.* 75: 41–52.
- Chae, J.S., Allsopp, B.A., Waghela, S.D., Park, J.H., Kakuda, T., Sugimoto, C., Allsopp, M.T., Wagner, G.G. and Holman, P.J. 1999. A study of the systematics of *Theileria* spp. based upon small-subunit ribosomal RNA gene sequences. *Parasitol. Res.* 85: 877–883.
- Daniels, P.W., Halpin, K., Hyatt, A. and Middleton, D. 2007. Infection and disease in reservoir and spill over hosts: determinants of pathogen emergence. *Curr. Top. Microbiol. Immunol.* 315: 113–131.
- Dolan, T.T. 1986. Chemotherapy of East Coast fever: The long term weight changes, carrier state and disease manifestations of parvaquone treated cattle. *J. Comp. Pathol.* 96: 137.
- Durrani, A.Z. and Kamal, N. 2008. Identification of ticks and detection of blood protozoa in friesian cattle by polymerase chain reaction test and estimation of blood parameters in district Kasur, Pakistan. *Trop. Anim. Health Prod.* 40(6): 441-447.
- Fuehrer, H.P., Biro, N., Harl, J., Worliczek, H.L., Beiglböck, C., Farkas, R., Joachim, A. and Duscher, G.G. 2013. Molecular detection of *Theileria* sp. ZS TO4 in red deer (*Cervus elaphus*) and questing *Haemaphysalis concinna* ticks in Eastern Austria. *Vet. Parasitol.* 197(3-4): 653–657.
- Galuppi, R., Aureli, S., Bonoli, C., Caffara, M. and Tampieri, M. P. 2010. Detection and molecular characterization of *Theileria* sp. in fallow deer (*Dama dama*) and ticks from an Italian natural preserve. *Res. Vet. Sci.* 24: 61-69.
- Garcia-Sanmartin, J., Aurtenetxe, O., Barral, M., Marco, I., Lavin, S., Garcia-Perez, A.L. and Hurtado, A. 2007. Molecular detection and characterization of piroplasms infecting cervids and chamois in Northern Spain. *Parasitology* 134: 391–398.
- Garner, B.C., Holman, P. and Berent, L.M. 2012. Theileriosis in a reindeer (*Rangifer tarandus tarandus*) associated with a potentially novel *Theileria* sp. *Vet Clin Pathol.* 41(4): 497–501.
- Gitau, G.K., Perry, B.D. and McDermott, J.J. 1999. The incidence, calf morbidity and mortality due to *Theileria parva* infections in small holder dairy farms in Murang'a District, Kenya. *Prev. Vet. Med.* 39(1): 65-79.
- Han, J.I., Jang, H.J. and Na, K.J. 2009. Molecular detection of *Theileria* sp. in wild Chinese water deer (*Hydropotes inermis argyropus*). *J. Wildl. Dis.* 45: 1213–1216.
- Hammer, J.F., Jenkins, C., Bogema, D. and Emery, D. 2016. Mechanical transfer of *Theileria orientalis*: possible roles of biting arthropods, colostrum and husbandry practices in disease transmission. *Parasites Vectors* 9: 34.
- Höfle, U., Vicente, J., Nagore, D., Hurtado, A., Pena, A., de la Fuente, J. and Gortazar, C. 2004. The risks of translocating wildlife. Pathogenic infection with *Theileria* sp. and *Elaeophora elaphi* in an imported red deer. *Vet. Parasitol.* 126: 387–395.
- Ikawa, K., Aoki, M., Ichikawa, M. and Itagaki, T. 2011. Occurrence of two distinct *Theileria* lineages in sika deer (*Cervus nippon*) of Iwate Prefecture. *Japan J. Vet. Med. Sci.* 73(10): 1371–1373.
- Inokuma, H., Tsuji, M., Kim, S.J., Fujimoto, T., Nagata, M., Hosoi, E., Arai, S., Ishihara, C. and Okuda, M. 2004. Phylogenetic analysis of *Theileria* sp. from sika deer, *Cervus nippon*, in Japan. *Vet. Parasitol.* 120: 339–345.

- Kakati, P., Sarmah, P.C., Bhattacharjee, K., Bhuyan, D. and Baishya, B.C. 2015. Molecular detection and associated pathogenesis in a fatal case of *Theileria orientalis* infection in India: Probable circulation of a virulent strain and stress associated factors. *Int. J. Recent Sci. Res.* **6**: 4235-4239.
- Khan, M.G.A. 1981. Theileriosis in a gaur calf (*Bos gaurus*). *Indian Vet. J.* **58**:72-73.
- Kjemtrup, A.M., Thomford, J., Robinson, T. and Conrad, P.A. 2000. Phylogenetic relationships of human and wildlife piroplasmisolates in the western United States inferred from the 18S nuclear small subunit RNA gene. *Parasitology* **120**: 193-487.
- Kocan, A.A. and Kocan, K.M. 1991. Tick-transmitted protozoan diseases of wildlife in North America. *Bull. Soc. Vector Ecol.* **16**: 94-108.
- Kohli, S., Atheya, U.K. and Thapliyal, A. 2014. Prevalence of theileriosis in cross-bred cattle: its detection through blood smear examination and polymerase chain reaction in Dehradun district, Uttarakhand, India. *Vet. World* **7**(3): 168-171.
- Liu, J., Yang, J., Guan, G., Liu, A., Wang, B., Luo, J. and Yin, H. 2016. Molecular detection and identification of piroplasms in sika deer (*Cervus nippon*) from Jilin Province, China. *Parasites Vectors* **9**: 156.
- Mans, B.J., Pienaar, R. and Latif, A.A. 2015. A review of *Theileria* diagnostics and epidemiology. *Int. J. Parasitol. Parasites Wildlife.* **4**: 104-118.
- Nijhof, A.M., Pillay, V., Steyl, J., Prozesky, L., Stoltz, W.H., Lawrence, J.A., Penzhorn, B.L. and Jongejan, F. 2005. Molecular characterization of *Theileria* species associated with mortality in four species of African Antelopes. *J. Clin. Microbiol.* **43**(12): 5907-5911.
- Ogre, P.B. 1999. Assessment of natural Ixodid tick infestation. *J. Vet. Med.* **46**: 405-419.
- Parthiban, M., Saranya, R., Magesh, M. and Raman, M. 2010. Detection of *Theileria* parasite in cattle of Tamilnadu using nested PCR. *Tamilnadu J. Vet. Anim. Sci.* **6**: 162-165.
- Radostitis, O.M, Gay, C.C, Hinchcliff, K.W and Constable, P.D. 2009. *Veterinary Medicine: A text book of the diseases of cattle, sheep, goat, pigs and horses*, 10<sup>th</sup> edn. Saunders Ltd., London. pp. 1526-1531.
- Roy, K.C., Ray, D., Bansal, G.C. and Singh, R.K. 2000. Detection of *Theileria annulata* carrier cattle by PCR. *Indian J. Exp. Biol.* **28**: 283-284.
- Sawczuk, M., Maciejewska, A. and Skotarczak, B. 2008. Identification and molecular characterization of *Theileria* sp. infecting red deer (*Cervus elaphus*) in north western Poland. *Eur. J. Wildl. Res.* **54**: 225-230.
- Schaeffler, W.F. 1961. *Theileria* in white-tailed deer in the United States. *J. Protozool.* **8**: 10.
- Silveira, J.A., Rabelo, E.M., Lacerda, A.C., Borges, P.A., Tomás, W.M., Pellegrin, A.O., Tomich, R.G. and Ribeiro, M.F. 2013. Molecular detection and identification of hemoparasites in pampas deer (*Ozotoceros bezoarticus* L. 1758) from the Pantanal Brazil. *Ticks Tick Borne Dis.* **4**(4):341-345.
- Tait, A. and Hall, F.R. 1990. *Theileria annulata*: control measures, diagnosis and the potential use of subunit vaccines. *Rev. Sci. Technol.* **9**(2): 387-403.
- Zanet, S., Trisciuglio, A., Bottero, E., Fernández de Mera, I.G., Gortazar, C., Carpignano, M.G. and Ferroglio, E. 2014. Piroplasmosis in wildlife: Babesia and *Theileria* affecting free-ranging ungulates and carnivores in the Italian Alps. *Parasites Vectors* **7**: 70.